

Effectiveness of Favipiravir prior to Admission to the Intensive Care Unit in COVID-19 Pneumonia

COVID-19 Pnömonisinde Yoğun Bakım Ünitesi Öncesinde Favipiravir'in Etkinliği

Önder Öztürk¹, Volkan Bağlan¹, Onur Kaya², Esra Nurlu Temel², Onur Ünal², Veysel Atilla Ayyıldız³, Mümtaz Cem Şirin⁴, Fevziye Burcu Şirin⁵, Gül Ruhsar Yılmaz², Füsün Zeynep Akcam², Münire Çakır¹, Ahmet Akkaya¹

Abstract

After emerging in Wuhan city in December 2019, the coronavirus disease 2019 (COVID-19) rapidly spread throughout China. Although high rates of hospitalization are seen with COVID-19, no specific treatment has been reported, and the choice of antiviral therapies is limited. Favipiravir, approved in Japan for influenza, is one of the drugs that targets RNA-dependent RNA polymerase (RdRP). It significantly decreases the duration of fever, cough dyspnea, and the need of oxygen therapy or noninvasive mechanical ventilation, especially in moderate COVID-19 cases. In the current paper we presented four cases with worsening clinical conditions and the development of hypoxia who were treated with Favipiravir before being admitted to the intensive care unit, and who recovered from the disease.

Key words: SARS-CoV-2 (COVID-19), antiviral treatment, favipiravir.

Özet

Aralık 2019'da Wuhan şehrinde ortaya çıkmasından bu yana, koronavirüs hastalığı (COVID-19) Çin'e hızla yayıldı. COVID-19 enfeksiyonuna bağlı yüksek oranda hastaneye yatış görülmesine rağmen, spesifik bir tedavi bildirilmemiştir. Bu bağlamda antiviral tedavi seçimi sınırlıdır. Japonya'da influenza için onaylanan Favipiravir, RNA'ya bağımlı RNA polimerazı (RdRP) hedefleyen ilaçlardan biridir. Özellikle orta şiddetteki COVID-19 olgularında ateş, öksürük dispnesi ve oksijen tedavisi veya noninvazif mekanik ventilasyon ihtiyacını önemli ölçüde azalttığı bilinmektedir. Bu yazıda, hastaları yoğun bakım ünitesine kabul etmeden önce klinik durumları kötüleşen ve favipiravir ile takip edilerek iyileşen dört olguyu sunduk.

Anahtar Sözcükler: SARS-CoV-2 (COVID-19), antiviral tedavi, favipiravir.

¹Department of Chest Diseases, Faculty of Medicine, Süleyman Demirel University, Isparta, Turkey

²Department of Infection Diseases, Faculty of Medicine, Süleyman Demirel University, Isparta, Turkey

³Department of Radiology, Faculty of Medicine, Süleyman Demirel University, Isparta Turkey

⁴Department of Medical Microbiology, Faculty of Medicine, Süleyman Demirel University, Isparta, Turkey

⁵Department of Medical Biochemistry, Faculty of Medicine, Süleyman Demirel University, Isparta, Turkey

¹Süleyman Demirel Üniversitesi, Tıp Fakültesi, Göğüs Hastalıkları Anabilim Dalı, Isparta

²Süleyman Demirel Üniversitesi, Tıp Fakültesi, Enfeksiyon Hastalıkları Anabilim Dalı, Isparta,

³Süleyman Demirel Üniversitesi, Tıp Fakültesi, Radyoloji Anabilim Dalı, Isparta

⁴Süleyman Demirel Üniversitesi, Tıp Fakültesi, Klinik Mikrobiyoloji Anabilim Dalı, Isparta

⁵Süleyman Demirel Üniversitesi, Tıp Fakültesi, Klinik Biyokimya Anabilim Dalı, Isparta

Submitted (Başvuru tarihi): 23.06.2020 **Accepted (Kabul tarihi):** 29.07.2020

Correspondence (İletişim): Önder Öztürk, Department of Chest Diseases, Faculty of Medicine, Süleyman Demirel University, Isparta, Turkey

e-mail: dronderozturk@gmail.com



Coronavirus disease 2019 (COVID-19) is a viral respiratory disease caused by the 2019 novel coronavirus (SARS-CoV-2) that has spread rapidly throughout China, and from there to the rest of the World. The SARS-CoV-2 outbreak has resulted in high rates of hospitalization and intensive care unit (ICU) admissions all over the world (1). Although high rates of hospitalization are seen, only a limited number of treatments are available, such as oseltamivir, chloroquine, azithromycin, Favipiravir, lopinavir/ritonavir and tocilizumab, although no specific antiviral drugs have been shown to have clinical efficacy in COVID-19 (2).

Favipiravir, known originally as T-705 (3), is one of these antiviral drugs that strongly inhibit the RNA-dependent RNA polymerase (RdRP) of influenza and many other RNA viruses. It inhibits all the serotypes and strains of the influenza A, B and C viruses against which it has been tested, including those resistant to the currently approved neuraminidase inhibitors. The mechanism of Favipiravir, involving the direct inhibition of viral replication and transcription, makes it unique among other anti-influenza drugs. Since RdRP domains are not present in human cells and are conserved among RNA viruses, this distinct specific mechanism targeting viral RNA-dependent polymerases makes Favipiravir an attractive drug candidate (4). SARS-CoV-2 and influenza viruses are both RNA viruses that depend on viral RNA-dependent RNA polymerase (RdRp) replication (5). It was approved for the treatment of a novel virus on February 15, 2020 in China and is currently undergoing clinical trials for the treatment of COVID-19, especially in the intensive care unit (ICU).

Favipiravir has proven to be more effective than other drugs in improving clinical outcomes and recovery rates, and alleviating fever, cough and breathing difficulties, being particularly superior to drugs for ICU use. Unlike the in standard approach, the patients were treated with Favipiravir prior to admittance to the ICU when the patients' clinical conditions were worsening and hypoxia was developing.

CASE

COVID-19-positive cases, diagnosed based on RT-PCR testing for SARS-CoV-2, are hospitalized and treated in line with the guidelines established by the Ministry of Health of the Republic of Turkey. Written informed consent was obtained from the patients presented here.

Case 1: A 65-year-old man with a history of hypertension and prostate hypertrophy was admitted with fever, cough and radiological findings compatible with COVID-19

(Figure 1). The initial treatment was oseltamivir, hydroxychloroquine, azithromycin and ceftriaxone (2x1gr). Although his good general condition, the treatment regimen was changed to meropenem, linezolid, moxifloxacin, methylprednisolone (1mg/kg) and favipiravir (initial: 2x1600mg, maintenance: 2x600mg for five days) due to hypoxemia and worsening laboratory findings on third day of the hospitalization (Table 1). On the seventh day of hospitalization, the patient's clinical and laboratory findings were within the normal range, with pulse oxygen saturation of 90% without symptoms of COVID-19.

Case 2: A 62-year-old man with a history of diabetes mellitus was admitted with cough, shortness of breath, fever and the radiological findings compatible with COVID-19 (Figure 2). The initial treatment included oseltamivir and hydroxychloroquine. On the third day of the hospitalization, the treatment regimen was changed to ceftriaxone (2x1gr), methylprednisolone (1mg/kg) and Favipiravir (initial: 2x1600mg, maintenance: 2x600mg for five days) after a worsening of clinical and laboratory findings (Table 1). Under oxygen therapy of 6 l/min, saturation increased from 80% to 89% (PaO₂/FiO₂: 228). On the seventh day of the hospitalization, the patient's clinical and laboratory findings were within the normal range, with pulse oxygen saturation of 94% and no symptoms of COVID-19.

Case 3: A 58-year-old man with a history of diabetes mellitus and coronary artery disease was admitted with cough, fever and radiological changes compatible with COVID-19 (Figure 3). The initial treatment included oseltamivir, hydroxychloroquine, azithromycin and 4000 anti-Xa IU enoxaparin sodium. On the fifth day of hospitalization, the patient's pulse and oxygen saturation decreased to 86% with dyspnea, and CRP increased to 152.77 mg/l, and so treatment was changed to ceftriaxone (2x1gr), theophylline, 4000 anti-Xa IU enoxaparin sodium, methylprednisolone (1mg/kg) and Favipiravir (initial: 2x1600mg, maintenance: 2x600mg for five days). In addition to medical treatment, oxygen saturation was kept between 85–89% using a reservoir mask (10–12 l/min.), and prone ventilation was provided before admission to the ICU. Oxygen saturation was >90% without oxygen supply after Favipiravir treatment. The patient was discharged once an RT-PCR test for COVID-19 was negative and no symptoms were present.

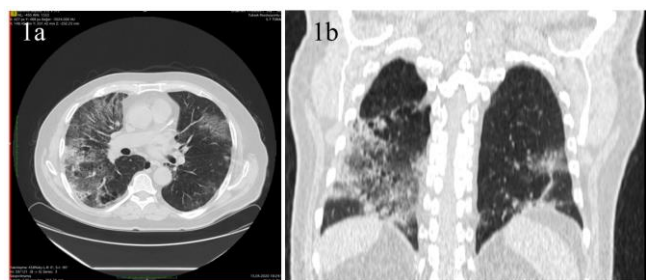

Figure 1a and b: Axial and coronal plane chest CT. In the form of bilateral peripheral consolidated areas, areas with the ground-glass density that affect the large part of both lungs are observed

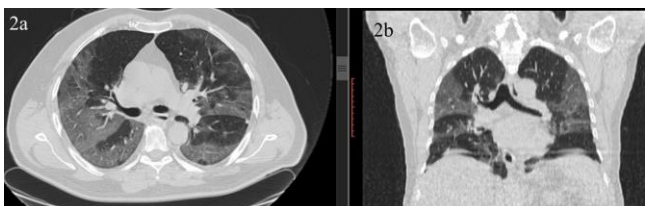


Figure 2a and b: Axial and coronal plane images of Chest CT. In the form of bilateral peripheral consolidated areas, areas with the ground-glass density that affect the large part of both lungs are observed

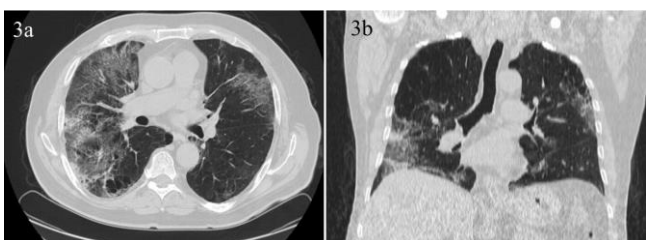


Figure 3a and b: Axial and coronal plane images of Chest CT. Parenchymal ground glass infiltrations, more pronounced on the right

Case 4: A 62-year-old man with a history of hypertension was admitted with cough and the radiological findings compatible with COVID-19 (Figure 4). The initial treatment was oseltamivir, hydroxychloroquine and azithromycin, however, the disease subsequently progressed to hypoxemic respiratory failure with increased body temperature, warranting the initiation of invasive mechanical ventilation (Table 1). Oxygen saturation was 90% with an 8 l/min oxygen supply ($\text{PaO}_2/\text{FiO}_2$: 200). The treatment regimen was changed to ceftriaxone IV (2x1gr), oral methylprednisolone (1mg/kg) and Favipiravir (initial: 2x1600mg, maintenance: 2x600mg) on the fifth day of hospitalization, after which improvement was noted in clinical and laboratory findings. Oxygen saturation was 95% with a 3 l/min oxygen supply on the fourth day of treatment. On the 10th day of the medical treatment, pulse oxygen saturation was 90% without oxygen therapy, and the patient was discharged with no symptoms of COVID-19.

During follow-up, the radiological recovery of the lungs could not be ascertained through thorax CT or posterior-

anterior (PA) chest film in our cases, although in one case (Case 4), recovery was noted in a radiological follow-up with chest films.

DISCUSSION

COVID-19 continues to spread at a rapid speed in the absence of any effective treatment or prophylactic agent. In this case series, Favipiravir was used as antiviral therapy in patients with severe COVID-19 (+) to prevent the need for intensive care, and was found to be successful as a treatment in this regard.

Favipiravir, approved in Japan for influenza, is an antiviral drug targeting RNA-dependent RNA polymerase (RdRP), and is considered to be a potential candidate for the treatment of COVID-19 (5-7). Chang C et al. (5) compared the clinical efficacy and safety of Favipiravir with that of umifenovir as a treatment for COVID-19 in a randomized clinical trial, and reported that Favipiravir did not improve the clinical recovery rate (61.21%) when compared to the umifenovir group (51.67%). It did, however, significantly improve the latency to relief for cough and decreased the duration of fever. The post-doc analysis also found Favipiravir treatment to significantly decrease de novo incidences of dyspnea, and the need for oxygen therapy or noninvasive mechanical ventilation, especially in moderate COVID-19 cases. These results suggest that Favipiravir may be effective in halting disease progression into ARDS, shock and multiple organ failure in moderate COVID-19 patients (5). In a non-randomized control trial, Favipiravir recorded significantly better treatment effects against disease progression and the viral clearance of COVID-19. Although the treatment duration with Favipiravir was twice as long as that used for the treatment of influenza, the adverse effects were rare and tolerable. The authors of the study stated that the treatment duration with Favipiravir may be prolonged if necessary, and that it may be considered an effective treatment for COVID-19 (3). The present study included patients who were clinically deteriorating, confirmed by

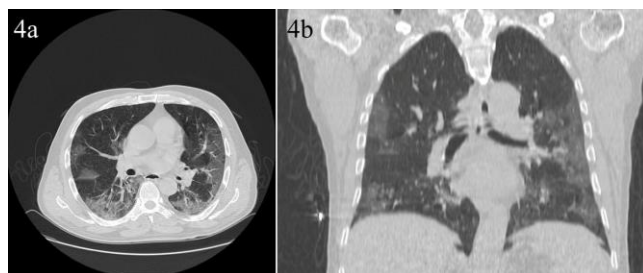


Figure 4a and b: Axial and coronal plane images of Chest CT. Bilateral, ground glass densities in the form of consolidated areas, more prominent in the middle-lower zones were seen

Table 1: Clinical Characteristics and Laboratory Results

Characteristics	Case 1	Case 2	Case 3	Case 4
Days from the disease onset to favipiravir therapy	3	3	5	5
"Laboratory findings" before favipiravir therapy				
WBC (per mm ³) (5.2-12.4)	4300	7300	4000	5900
Differential count (per mm ³)				
Total neutrophils (2.1-6.1)	3.6	5.5	3.5	5.1
Total lymphocytes (1.3-3.5)	0.5	0.8	0.4	0.5
Total monocytes (0.3-0.9)	0.2	0.5	0.1	0.2
PLT (per mm ³) (156-373)	141	369	171	206
HGB (g/dL) (13.6-17.2)	14.2	13.9	14	13.3
Glucose (mg/dL) (74-106)	102.06	197.74	212.84	101.46
Albumin(g/liter) (3.5-5.2)	-	-	3.62	2.91
ALT (U/liter) (0-34)	57.03	48.81	26.25	29.77
AST (U/liter) (0-31)	87.38	41.67	35.33	41.46
LDH (U/liter) (0-247)	753.78	363.71	407.82	318.9
Cr (mg/dL) (0.67-1.17)	1.2	0.72	0.76	0.71
CPK (U/liter) (26-308)	656.43	-	226.36	53.14
EGFR (ml/min/1.73 m ²)	63.52	100.68	100.57	100.00
Troponin T (ng/ml)(0-0.014)	0.008	0.006	0.004	0.003
PT (sec) (9.4-112.5)	13.4	14.9	14.7	12.6
aPTT (sec) (25.4-38.4)	30.6	20.5	32.3	34.3
Fibrinogen (mg/dL) (200-393)	563	609	500	683
D-dimer (ng/ml) (69-243)	328	920	816	874
Serum ferritin (ng/ml) (28-365)	>1920	1682	610.4	862.3
Procalcitonin (ng/ml) (<0.5 negative)	0.073	0.086	0.081	0.072
CRP (mg/liter) (0-5)	92.80	144.48	152.77	126.38
Blood Gases				
Laktat	2.73	1.29	2.52	1.74
Ph	7.40	7.53	7.39	7.44
PCO ₂ (mmHg)	35.2	26.4	37.6	41.6
PO ₂ (mmHg)	44.7	64.3	45.4	31.2
SatO ₂ %	-	92.4	-	54
HCO ₃ act(mmol/mL)	21.5	21.9	22.7	27.4

EGFR: estimated glomerular filtration rate, High-sensitivity C-reactive protein: CRP, Activated partial thromboplastin time: aPTT, Prothrombin time: PT, Creatine kinase: CPK, Lactate dehydrogenase: LDH, Aspartate aminotransferase: AST, Alanine aminotransferase: ALT, White-cell count: WBC, Platelet count. PLT, Hemoglobin: HBG, Creatinine: Cr

laboratory and radiology findings, while being treated following a diagnosis of COVID-19. We found Favipiravir treatment to be effective in decreasing the need for oxygen therapy, and in decreasing the symptoms of fever and dyspnea in our patients, as described previously in medical literature. However, unlike the previous findings in the literature, it was found also to improve clinical

outcomes and recovery rate, and the disease did not progress to septic shock, multiple organ failure or ICU admission.

In conclusion, we found Favipiravir to be effective in the treatment of COVID-19 patients and in reducing admissions to the ICU. This might be attributed to the prevention of virus replication and to the reduction of the anti-

genic load of the COVID-19 virus and cytokine production. We suggest, therefore, using Favipiravir as the first choice antiviral therapy in COVID-19 patients at the beginning, although randomized wide-ranging studies are needed to show its full effects.

CONFLICTS OF INTEREST

None declared.

AUTHOR CONTRIBUTIONS

Concept - Ö.Ö., V.B., O.K., E.N.T., O.Ü., V.A.A., M.C.Ş., F.B.Ş., G.R.Y., F.Z.A., M.Ç., A.A.; Planning and Design - Ö.Ö., V.B., O.K., E.N.T., O.Ü., V.A.A., M.C.Ş., F.B.Ş., G.R.Y., F.Z.A., M.Ç., A.A.; Supervision - Ö.Ö., V.B., O.K., E.N.T., O.Ü., V.A.A., M.C.Ş., F.B.Ş., G.R.Y., F.Z.A., M.Ç., A.A.; Funding - Ö.Ö., V.B.; Materials - M.C.Ş., F.B.Ş.; Data Collection and/or Processing - O.Ü., V.A.A.; Analysis and/or Interpretation - A.A., G.R.Y., F.Z.A.; Literature Review - E.N.T., V.B.; Writing - Ö.Ö.; Critical Review - A.A., M.Ç.

YAZAR KATKILARI

Fikir - Ö.Ö., V.B., O.K., E.N.T., O.Ü., V.A.A., M.C.Ş., F.B.Ş., G.R.Y., F.Z.A., M.Ç., A.A.; Tasarım ve Dizayn - Ö.Ö., V.B., O.K., E.N.T., O.Ü., V.A.A., M.C.Ş., F.B.Ş., G.R.Y., F.Z.A., M.Ç., A.A.; Denetleme - Ö.Ö., V.B., O.K., E.N.T., O.Ü., V.A.A., M.C.Ş., F.B.Ş., G.R.Y., F.Z.A., M.Ç., A.A.; Kaynaklar - Ö.Ö., V.B.; Malzemeler - M.C.Ş., F.B.Ş.; Veri Toplama ve/veya İşleme - O.Ü., V.A.A.; Analiz ve/veya Yorum - A.A., G.R.Y., F.Z.A.; Literatür Taraması - E.N.T., V.B.; Yazıyı Yazan - Ö.Ö.; Eleştirel İnceleme - A.A., M.Ç.

REFERENCES

1. Grasselli G, Pesenti A, Cecconi M. Critical care utilization for the COVID-19 outbreak in Lombardy, Italy: early experience and forecast during an emergency response. *JAMA* 2020 (In press). [\[CrossRef\]](#)
2. Zhou F, Yu T, Du R, Fan G, Liu Y, Liu Z, et al. Clinical course and risk factors for mortality of adult inpatients with COVID-19 in Wuhan, China: a retrospective cohort study. *Lancet* 2020; 395(10229):1054-62. [\[CrossRef\]](#)
3. Furuta Y, Komeno T, Nakamura T. Favipiravir (T-705), a broad-spectrum inhibitor of viral RNA polymerase. *Proc Jpn Acad Ser B Phys Biol Sci* 2017; 93:449-63. [\[CrossRef\]](#)
4. ClinicalTrials.gov [Internet]. Bethesda (MD): National Library of Medicine (US). 2020 Mar 12 – Identifier NCT04303299, Various combinations of Protease Inhibitors, Oseltamivir, Favipiravir, and Chloroquine for Treatment of COVID-19: A Randomized Control Trial (THDMS-COVID19).
5. Chang C, Yi Z, Jianying H, Ping Y, Zhenshun C, Jianyuan W, et al. Favipiravir versus Arbidol for COVID-19: A Randomized Clinical Trial. *medRxiv* 2020.03.17.20037432. [\[CrossRef\]](#)
6. Lu R, Zhao X, Li J, Niu P, Yang B, Wu H, et al. Genomic characterisation and epidemiology of 2019 novel coronavirus: implications for virüs origins and receptor binding. *Lancet* 2020; 395(10224):565-74. [\[CrossRef\]](#)
7. Cai Q, Yang M, Liu D, Chen J, Shu D, Xia J, et al. Experimental treatment with Favipiravir for COVID-19: an open-label control study. *Engineering (Beijing)* 2020 (In press). [\[CrossRef\]](#)